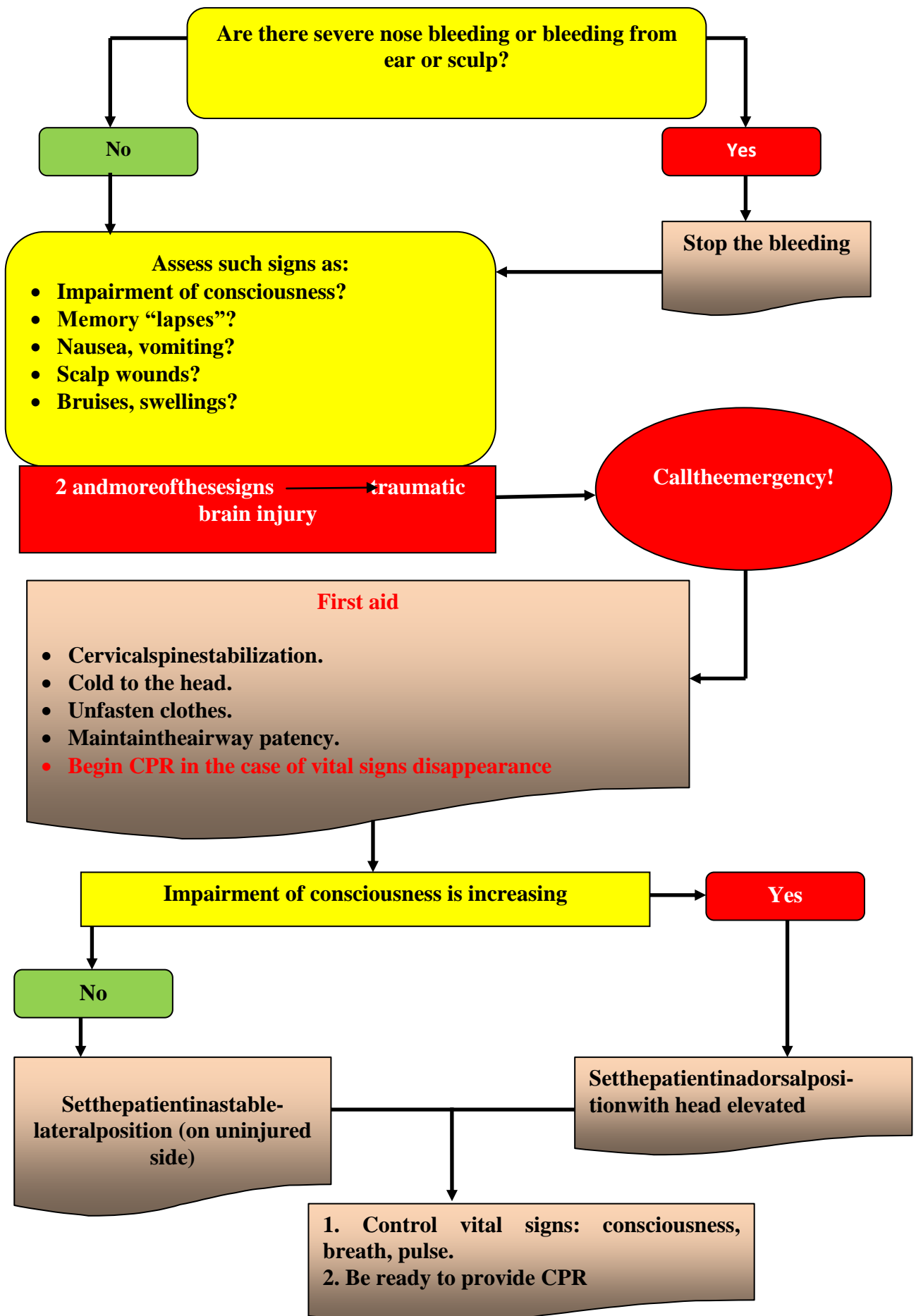


Topic 1.12 part 2. "First aid in the case of explosion, building failure, earthquake"

Scheme 1

Traumatic brain injury



Call the emergency immediately if you find out these signs:

- ✓ Severe bleeding;
- ✓ Bleeding from nose or ear;
- ✓ Severe headache;
- ✓ Absence of breathing;
- ✓ Impairment of consciousness or unconsciousness;
- ✓ Disturbance in the balance;
- ✓ Weakness in arms or legs, inability of movement;
- ✓ Convulsions;
- ✓ Repeated vomiting;
- ✓ Bad verbal communication.

It is necessary to call the emergency in the case of open cranio-cerebral trauma.

To assess the severity of brain injury and the depth of coma use **Glasgow coma scale**.

Glasgow coma scale consists from 3 tests, estimated the reaction of eyes opening (**E**), verbal response (**V**) and motor response (**M**).

E, Eye response

- Spontaneous — 4 points
- To sound — 3 points
- To pressure or to pain — 2 points
- None — 1 point

Table 1

Criterion	Rating	Score
Open before stimulus	Spontaneous	4
After spoken or shouted request	To sound	3
After fingertip stimulus	To pressure	2
No opening at any time, no interfering factor	None	1

V, Verbal response

- Orientated — 5 points
- Confused — 4 points
- Unrelated single words — 3 points

- Unrelated single sounds — 2 points
- None — 1 point

Table 2

Criterion	Rating	Score
Correctly gives name, place and date	Orientated	5
Not orientated but communication coherently	Confused	4
Intelligible single words	Words	3
Only moans / groans	Sounds	2
No audible response, no interfering factor	None	1

M, Motor response

- Obey commands — 6 points
- Purposeful movement as response on pain stimulation — 5 points
- Normal flexion as response on pain stimulation — 4 points
- Abnormal flexion as response on pain stimulation — 3 points
- Pathologic extension as response on pain stimulation — 2 points
- None — 1 point

Table 3

Criterion	Rating	Score
Obey 2-part request	Obeys commands	6
Brings hand above clavicle to stimulus on head neck	Localising	5
Bends arm at elbow rapidly but features not predominantly abnormal	Normal flexion	4
Bends arm at elbow, features clearly predomi-	Abnormal flexion	3

nantly abnormal		
Extends arm at elbow	Extension	2
No movement in arms / legs, no interfering factor	None	1

Generally, brain injury is classified as:

- Severe, GCS < 8–9
- Moderate, GCS 8 or 9–12
- Minor, GCS ≥ 13.

Summary (Total Coma Score)

- 15 points— fully consciousness.
- 14-13 points—moderate stupor.
- 12—11 points— severe stupor.
- 10—8 points—sopor.
- 7-6 points— moderate coma.
- 5-4 points— severe coma.
- 3 points— severe coma or cerebral death.

The scale can be applied without modification to children over 5 years old.

In younger children and infants, an assessment of a verbal response as “oriented” and motor response as “obeys commands” is usually not possible. A ‘Pediatric Glasgow Coma Scale’ was therefore described in Adelaide in which responses were modified as below.

E, Eye response

- Spontaneous – 4 points
- To sound— 3 points
- To pain stimulation — 2 points
- None — 1 point

V, Verbal response

- Talks or coos, smiles, monitors the object – 5 points
- Irritable cries – 4 points
- Cries in response to pain – 3 points
- Moans in response to pain – 2 points
- None – 1 point

M, Motorresponse

- Moves spontaneously/purposefully — 6 points
- Withdrawstotouch, localizes pain— 5 points
- Withdrawstopain — 4 points
- Flexiontopain— 3 points
- Extensiontopain — 2 points
- None — 1 point

Interpretationofresultsisthesameasforadults.

Firstaidfortraumaticbraininjury

1. Bleeding control in the case of open wound:
 - a) inthecaseofmildbleeding – coverthewound with dressing;
 - b) inthecaseofseverebleeding – carryoutfingerpressing of arterybefore bandaging.
2. Cervicalspine stabilization.
3. Place cold on the head.
4. Unfastenclothes.
5. Urgethepatienttocurbvomitingorcoughifitispossible (becauseoftheriskofincreasingofintracranialpressure).
6. Controlvitalfunctions.
7. Transportpositionifthe patientisconscious – dorsalpositionorrescuestablelateral-positionwithheadelevated.
8. Transportpositioninthecaseofimpairedconsciousness – stablelateralpositiononuninjured sidewith headelevated.
9. BereadytobeginCPRinthecaseof pulse or breathing absence.

Peculiaritiesofbraininjuryofchildren and infants:

- In the case of cerebral concussion, loss of consciousness is very short, sometimes it is difficult to define or fix it.
- Childissluggish, whiny.
- Headacheismildormoderate.

NB!

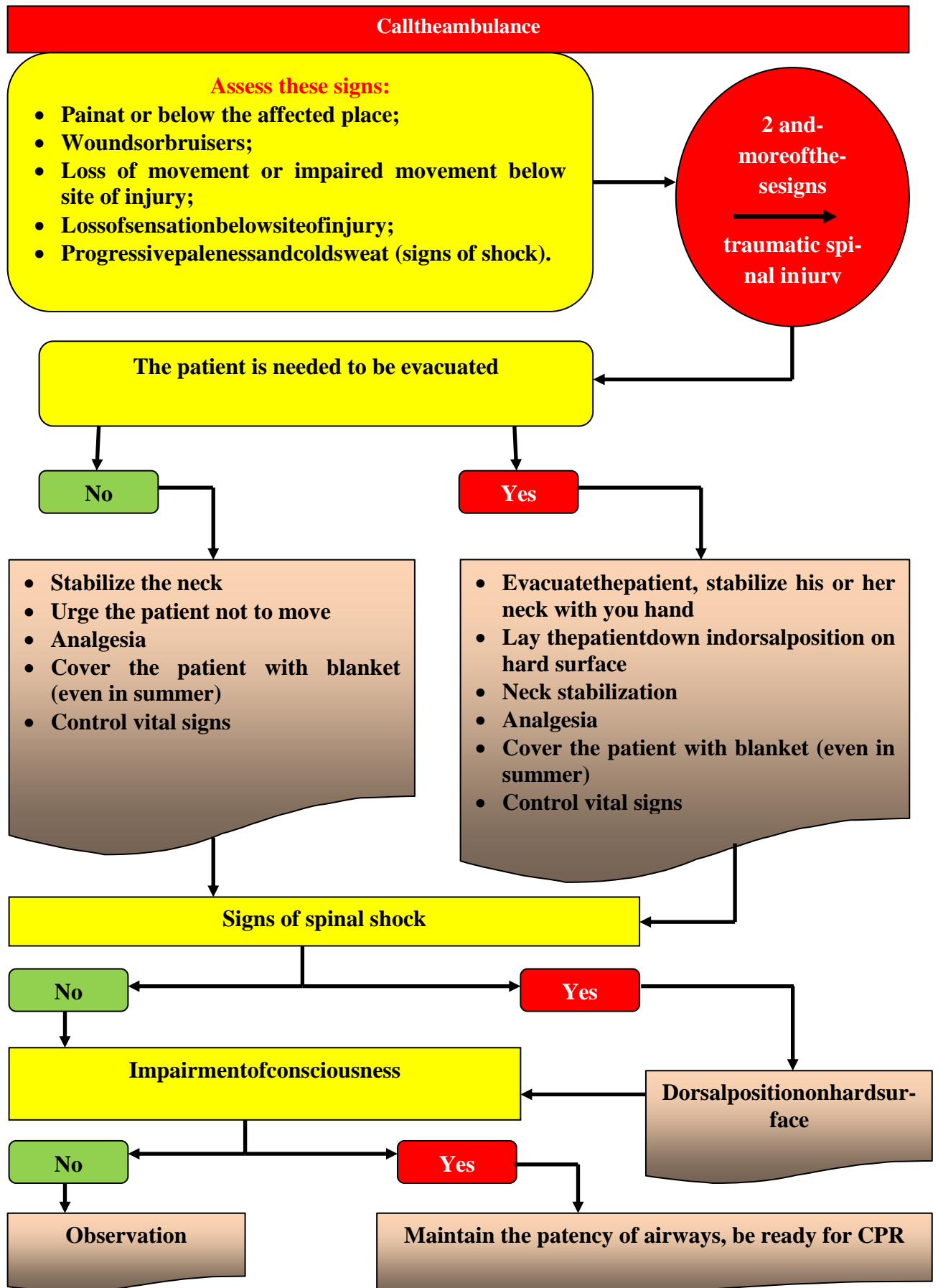
Itisprohibitedtodointhecaseofbrain injury:

- To setthepatientintothesitting position;
- To lift or move the patient;
- To leavethepatientwithout observation;

- To exclude going to the hospital.

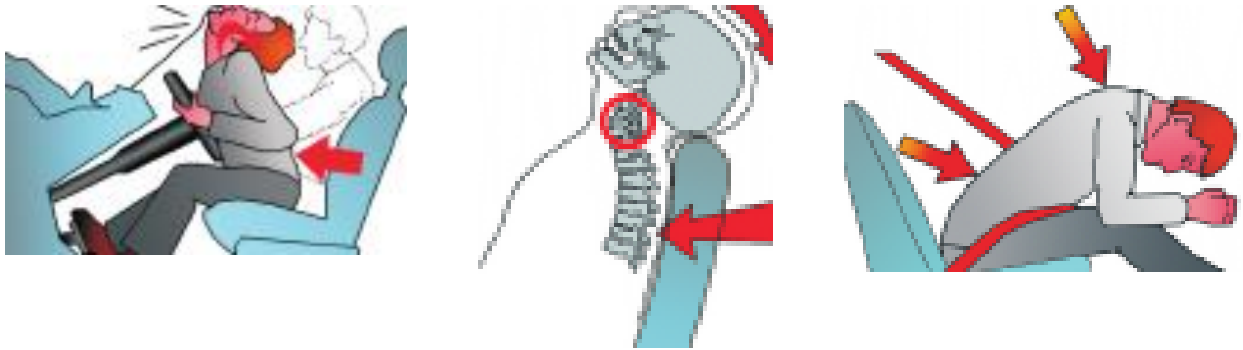
Spinal injuries.

Scheme 2



The more common injuries occur when the area of the spine or neck is bent or compressed, as in the following: falls, motor vehicle accidents (automobiles, motorcycles, and being struck as a pedestrian), sports injuries, diving accidents, trampoline accidents.

Traumas of spinal neck may occur in the case of hard braking with the header on the windscreen (pic.1), in the case of sharp flexion or extension of the neck (pic. 2,3)



Pic. 1 Pic. 2 Pic. 3

According to the nature of trauma, there are different kinds of spinal trauma:

- Compression;
- Flexion-distraction (with spinal rupture in horizontal plane);
- Rotary trauma.

In the case of spinal cervical trauma, the victim complains on:

- Occipital pain while head rotation;
- Restriction of head and neck movements;
- Pain while injured cervical vertebra palpation;
- Tension of the neck muscles.

In the case of trauma of lumbar-thoracic spine, the victim complains on:

- ✓ Severe pain at the affected vertebra immediately after trauma;
- ✓ Pain is increasing in sitting position and decreasing in dorsal position;
- ✓ Visible deformation, visible wound;
- ✓ Process of injured vertebra is painful, it may bulge;
- ✓ Muscles around the injury are tensioned;
- ✓ Abdominal pain and retention of urine are possible.

In the case of spinal cord injury:

- Spinal shock occurs immediately after trauma: sharp and severe decreasing of blood pressure;
- Loss of motor function below site of injury;

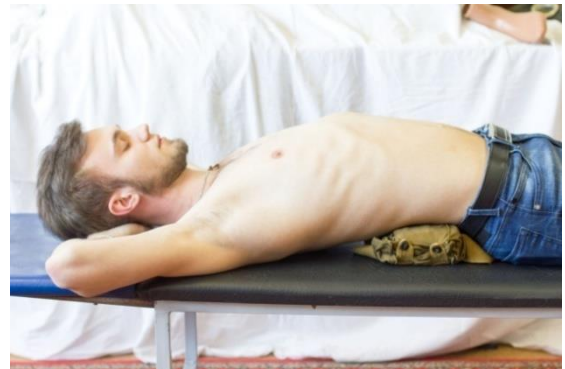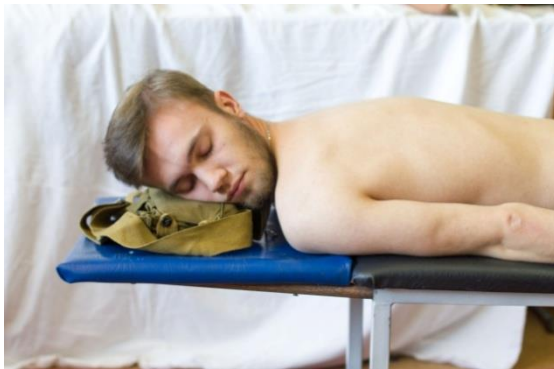- Loss of sensory below site of injury;
- Retention of urine;
- Impairment of thermoregulation, and as a result - undercooling (even in summer).

First aid

Stabilize the neck with your hands. **Don't use cervical collar!** According to the latest recommendations of American Heart Association, AHA and European Resuscitation Council, ERC (2015) the most appropriate method of spinal stabilization before emergency arriving is hand stabilization or even verbal instructions.

In the case of unconsciousness with definable pulse and breathing – maintain the patency of airways, control vital functions and be ready to begin CPR.

Try not to displace the patient, but if you need to evacuate the patient use 4 or 5 helpers, displace him carefully, avoid changing his position.



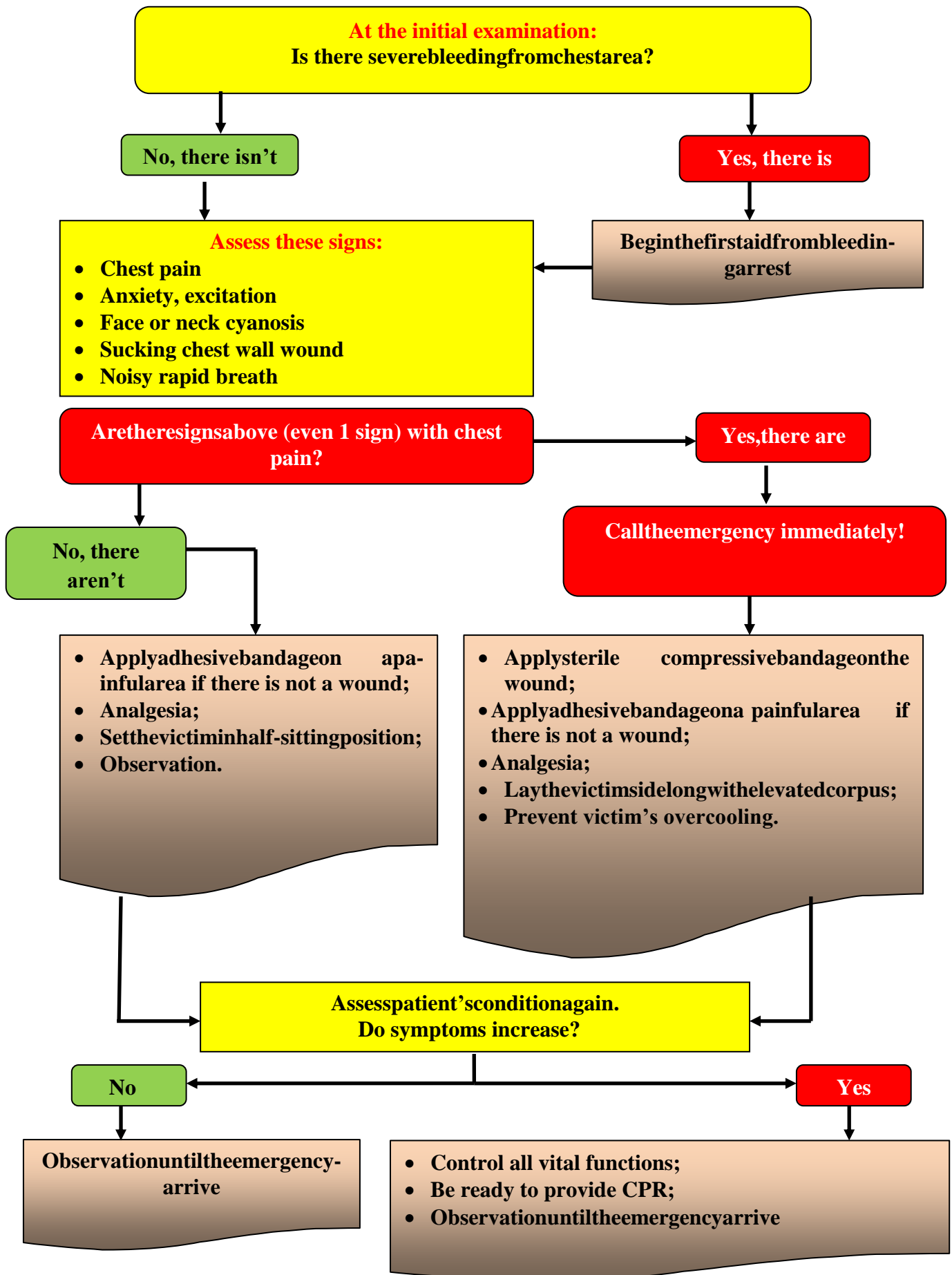
Pic. 4 Pic. 5

The appropriate position – dorsal position or ventral decubitus (pic. 4, 5) on hard surface. If you need to roll the patient into dorsal position from ventral – press tightly a shield to his back and roll him carefully with the shield.

Control all vital functions (breathing, pulse, consciousness) permanently. Cover the patient with a blanket even in summer to avoid overcooling.

Part 14. Chest injury

Scheme 3

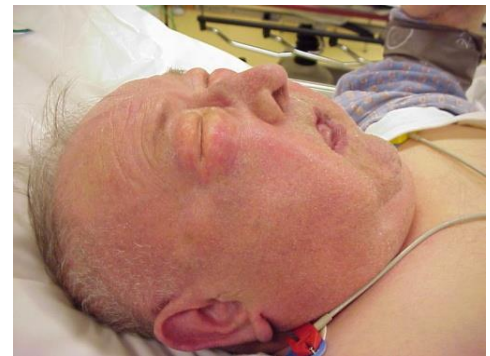
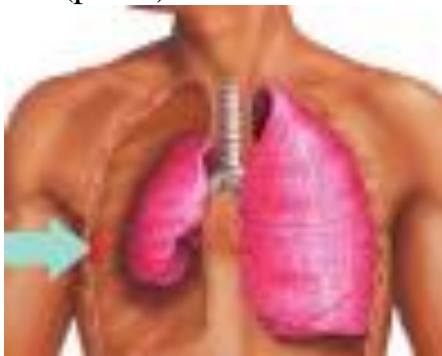

Trauma patients often present with a known traumatic mechanism such as a car collision, fall, gunshot or stab wound. In rare cases, a patient may present in a state of significant altered mental status and be unable to provide any significant history.

Main symptoms of chest injury:

- visible lesions of chest wall;
- pale skin, cyanosis of lips, nose, ears, finger tips;
- chestpain, painfulbreathing;
- asymmetryofrespiratorymovements (injuredpartfallsbehindhealthone);

In the case of open pneumothorax lung subsides on the side of pneumothorax (pic. 6)



Pic. 6Pic. 7Pic. 8

Patient's condition is severe: rapid and weak pulse, sucking air from the wound, crepitation around the wound, forced half-sitting position with straighten arm support.(pic.7)

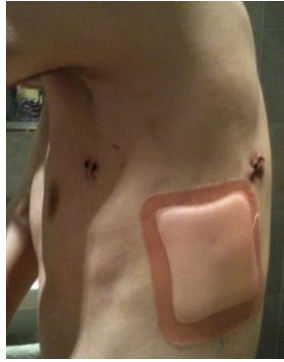Tension pneumothorax occurs in the case of lung trauma with bone fractures but without skin lesion. Air is forced into the pleural space without any means of escape, eventually completely collapsing the affected lung. The mediastinum is pushed to the opposite side, decreasing venous return and compressing the opposite lung. Subcutaneous emphysema spreads from face to groin and causes puffiness. (pic. 8)

Valvular pneumothorax occurs when one-way valve is formed by an area of damaged tissue, and the amount of air in the space between chest wall and lungs increases. This is the most dangerous kind of pneumothorax that can cause pleuro-pulmonary shock and mediastinal displacement.

You should determine air presence in pleural space before the treatment. Suspect air presence if you see shortness of breath, cyanosis of nasolabial triangle, ears, finger tips etc. In severe cases you may watch bulged cervical veins, rapid and superficial breath.

In the case of pneumothorax injured half of wall chest falls behind the health one while breathing.

If you suspect pneumothorax call the emergency immediately. If you see open pneumothorax turn it into closed pneumothorax by occlusive bandage application on the chest wound (pic. 9).



Pic. 9

You may make it from buckram or polyethylene film. The most effective variant is a valvular bandage that allows blood to drop from the wound but prevent air to get into the wound.

Provide comfortable position for patient's breathing with elevated corpus, use makeshift means for it. Do it carefully to prevent further suffering and pain.

First aid for mild respiratory failure

- Call the emergency;
- Find the most painful place and apply imbricate adhesive plaster (if there are no wounds);
- Set the victim to the comfortable position for breathing;
- Apply sterile bandage on the wound;
- Control all vital functions: pulse, breathing, consciousness.



Pic. 10

First aid for severe respiratory failure

- Calm down the patient, be in contact with him or her constantly;
- Find the most painful place and apply imbricate adhesive plaster (if there are no wounds);
- Lay the victim on the side of pneumothorax with lifted corpus (pic. 10);
- If the patient is unconscious set him or her into recovery position (lateral stable position) on the injured side with lifted corpus;
- Artificial lung ventilation if there is such a need;
- Apply sterile bandage on the wound;
- Prevent patient's overcooling;
- Control all vital functions: pulse, breathing, consciousness.
- Be ready to start CPR;

NB!

Do not remove foreign body from the chest wound;
Do not bandage chest wounds too tightly.

Honorable students!

After learning this material, you need to pass the test in Google-form. Please fill all gaps properly (name, faculty, number of your group).